

EDUCATIONAL RESOURCE

Title: A 3-Dimensional (3D) Paper Model of the Pterygopalatine Fossa for Anatomy Education

Authors: Muhammad Zaid Zainuddin, Norhayati Liaqat Ali Khan, Noor Azliza Wani Abd. Aziz, Mohd Maaruf Abdul Malik, Aimi Nadia Razlan, Andrean Husin

Submitted Date: 11-06-2024

Accepted Date: 06-11-2024

Please cite this article as: Zainuddin MZ, Ali Khan NL, Abd. Aziz NAW, Abdul Malik MM, Razlan AN, Husin A. A 3-dimensional (3D) paper model of the pterygopalatine fossa for anatomy education. Education in Medicine Journal. (early view).

This is a provisional PDF file of an article that has undergone enhancements after acceptance, such as the addition of a cover page and metadata, and formatting for readability, but it is not yet the definitive version of record. This version will undergo additional copyediting, typesetting and review before it is published in its final form, but we are providing this version to give early visibility of the article.

ARTICLE INFO

Submitted: 11-06-2024

Accepted: 06-11-2024

A 3-Dimensional (3D) Paper Model of the Pterygopalatine Fossa for Anatomy Education

Muhammad Zaid Zainuddin¹, Norhayati Liaqat Ali Khan¹,
Noor Azliza Wani Abd. Aziz¹, Mohd Maaruf Abdul Malik¹,
Aimi Nadia Razlan¹, Andrean Husin²

¹*Centre of Preclinical Science Studies, Faculty of Dentistry, Universiti Teknologi MARA, 47000 Sungai Buloh, Selangor, Malaysia*

²*Centre for Oral & Maxillofacial Surgery Studies, Faculty of Dentistry, Universiti Teknologi MARA, 47000 Sungai Buloh, Selangor, Malaysia*

ABSTRACT

The pterygopalatine fossa is a small pyramidal space located at both sides of the skull. It is complex due to the many structures that run through the fossa to communicate between different anatomical areas of the head. Being clinically important to oral and maxillofacial surgery, the anatomy of the pterygopalatine fossa is challenging to visualise for dental undergraduate preclinical students. To tackle this problem, we proposed a 3-dimensional (3D) paper model of the pterygopalatine fossa for dental undergraduate preclinical anatomy teaching and learning. This article outlines the step-by-step method for building a 3D paper model of the pterygopalatine fossa. This article also explains our teaching approach which integrates a spatial narrative component to anatomy education and a quiz to test students understanding before and after the activity. This study represents a practical approach to anatomical education in cases where 3D models of an anatomical area are unavailable. This study also attempts to integrate spatial narrative into anatomy education for better visual-spatial thinking and memory retention.

Keywords: *anatomy education, pterygopalatine fossa, paper model, spatial narrative, narrative visualisation*

CORRESPONDING

Muhammad Zaid Zainuddin, Centre of Preclinical Science Studies, Faculty of Dentistry, Universiti Teknologi MARA, 47000 Sungai Buloh, Malaysia

Email: zaidzainuddin@uitm.edu.my

INTRODUCTION

The pterygopalatine fossa is one of the most challenging anatomical areas for undergraduate dental students to master. The fossa is difficult to conceptualise due to its small size and volume and its poorly accessible location in the skull (1). Alongside the numerous neurovascular components that run through it, connecting multiple areas of the head, the pterygopalatine fossa is difficult to visualise using only 2-dimensional (2D) illustrations and cadaveric dissections.

Anatomically, the pterygopalatine fossa is a small pyramidal-shaped fossa located on the lateral aspects of the skull that acts as a major neurovascular junction between the oral cavity, nasopharynx, orbit, infratemporal fossa, and middle cranial fossa (2). The anatomical borders of the

pterygopalatine fossa respectively are the greater wing and lateral portion of the body of the sphenoid bone superiorly, the perpendicular plate of the palatine bone medially, the pterygoid process posteriorly, the posterior surface of the maxillary bone anteriorly, and the pterygomaxillary fissure laterally. Within these walls are the foramina that allow neurovascular structures to enter and exit the pterygopalatine fossa. Briefly, the pterygopalatine fossa is bounded laterally by the pterygomaxillary fissure that connects to the infratemporal fossa; medially by the sphenopalatine foramen which connects to the nasal cavity, inferiorly by the greater and lesser palatine canals which connects with oral cavity; anterosuperiorly by the inferior orbital fissure located at the superior aspect of the anterior wall connecting the pterygopalatine fossa with the orbit; and posteriorly by three foramina (foramen rotundum, the pterygoid canal, and the pharyngeal canal) which connects the pterygopalatine fossa to the middle cranial fossa and the nasopharynx. Regarding the contents of the pterygopalatine fossa, important structures of the pterygopalatine fossa include the pterygopalatine ganglion, one of the four-paired parasympathetic ganglions that reside in the head and neck region; the maxillary nerve (CNV2), the second branch of the trigeminal nerve which supplies sensory innervation to the middle third of the face; and the third part of the maxillary artery, which supplies certain areas of the head including the hard and soft palate, nasal cavity, upper lip, lower eyelid and maxillary dentition and gingiva (2). With regards to its application in dentistry, the pterygopalatine fossa and its contents are closely related to the specialization of oral and maxillofacial surgery involving dentofacial deformities such as maxillary osteotomy (3), as well as maxillary nerve blocks targeting the infraorbital nerve (4). Though these clinical applications are only introduced to dental students later in their dental undergraduate programme, a basic understanding of the anatomy of the pterygopalatine fossa is crucial in their preclinical years.

The teaching of the pterygopalatine fossa, apart from via the usual didactic lectures that are given in teaching institutions worldwide, has been incorporated with various innovative teaching methods such as using web-based programs, 3-dimensional (3D) printed models, serious gaming as well as virtual reality technology, to facilitate student understanding (5, 6, 7, 8). Though highly innovative and revolutionary, these methods require high cost and technical know-how that not all teaching institutions can afford. In an attempt to improve undergraduate teaching and learning of the pterygopalatine fossa without the application of advanced technology, we needed a teaching aid that is affordable, practical, and easy to make. We represented the pterygopalatine fossa as a 3D paper model that acts as a visual and kinesthetic learning tool to enable students to visualize the fossa, its boundaries, its communicating channels, and its neurovascular structures. This article proposes and outlines a step-by-step method for creating a 3D paper model of the pterygopalatine fossa. Alongside the paper model, this article explains our attempt to integrate a spatial narrative component into anatomy teaching and a quiz to test students' understanding before and after the activity..

METHODOLOGY

Creating a 3D Paper Model of the Pterygopalatine Fossa

As the pterygopalatine fossa is shaped like an inverted pyramid, we started with creating a pyramid template using an online template generator (9). The dimensions of the pyramid can be adjusted to the educators' and learners' preferences. On this template, the students would need to identify and label the walls, and the respective structures that make up the walls of the pterygopalatine fossa to determine the orientation and location of the respective foramina. Based on the walls identified, students would then need to mark and cut out the foramina of the pterygopalatine fossa as depicted in Figure 1. The pyramid template, with the foramina cut out, is then folded to form a 3D pyramidal shape as shown in Figure 2. A small portion of

the pyramid's apex is to be cut off, portraying the “greater and lesser palatine canals”. The pyramid can be coloured or decorated according to the preference of the student/teaching staff. To show the neurovascular components, primarily the maxillary artery and maxillary nerve, red and yellow pipe cleaners are used respectively. Figure 2 shows our depiction of the maxillary artery and maxillary nerve using the red and yellow pipe cleaners. Note that the insertion of the pipe cleaners is to illustrate the course of the respective neurovascular structures and should be guided by the anatomy teaching staff.

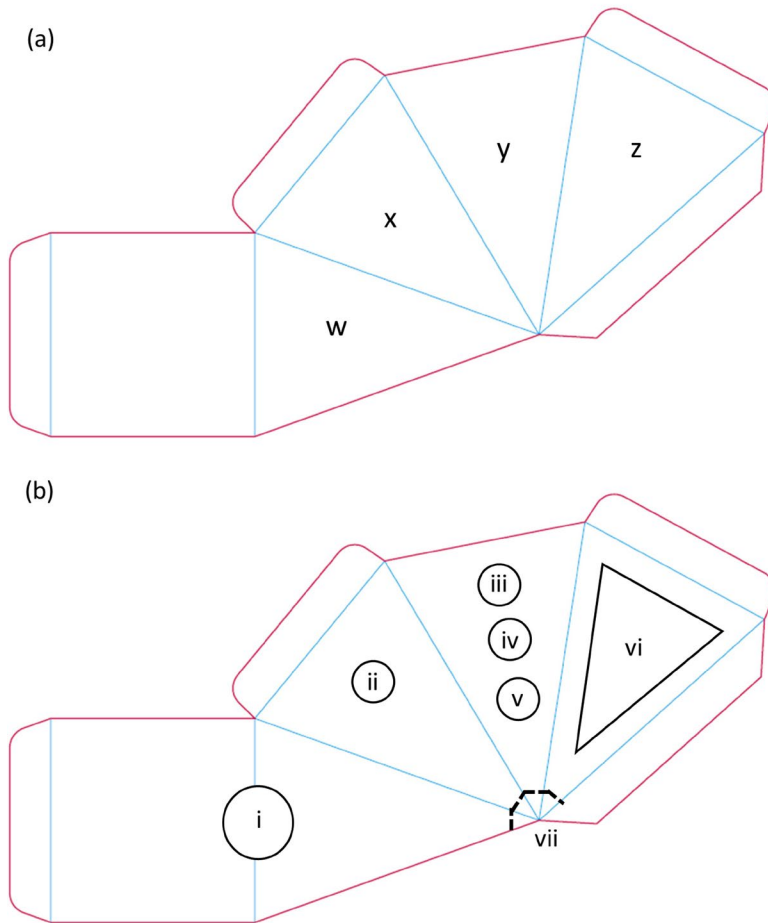


Figure 1

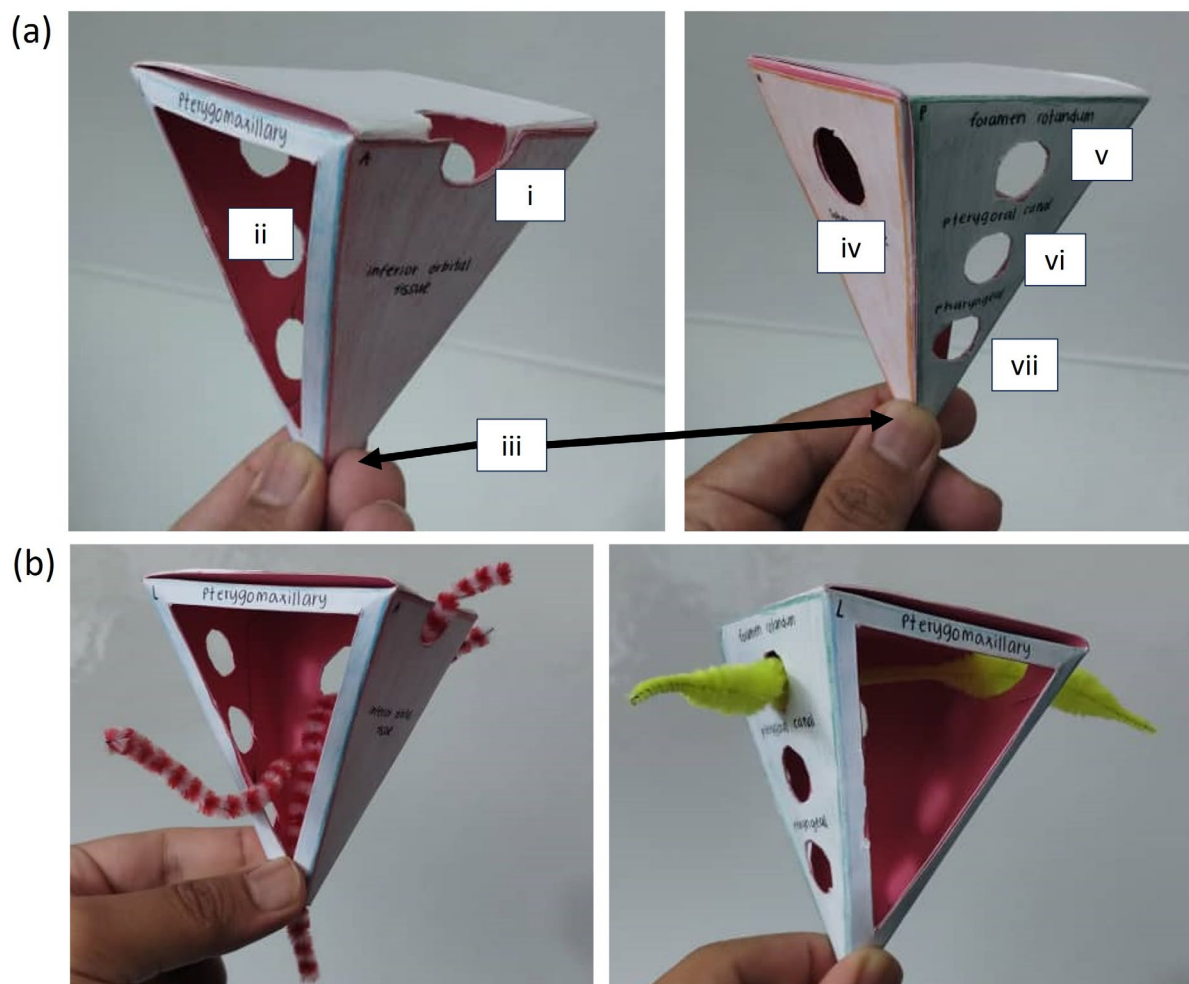


Figure 2

Teaching Approach

We attempted to integrate a spatial narrative approach to anatomy teaching by instructing students to imagine themselves being inside the pterygopalatine fossa, and to mentally visualise the structures related to the fossa from the inside. An example of anatomical explanation using a spatial narrative approach is as follows:

“Imagine yourself being inside your right pterygopalatine fossa. On your right (lateral) is the pterygomaxillary fissure and on your left (medial) is the sphenopalatine foramen. If you were to take one step through the pterygomaxillary fissure, you would end up in the infratemporal fossa, and if you were to take one step medially through the sphenopalatine foramen, you would end up in the nasal cavity. Posteriorly, just above your head is the foramen rotundum, and beneath it are the pterygoid canal and pharyngeal canal. In front of you, looking upwards, is the inferior orbital fissure that leads into the orbit. Underneath you are the greater and lesser palatine canals going into the oral cavity.”

When the students are able to mentally visualise and understand the space they are in, where

all the foramina are located, and how each foramina leads to different areas of the head, only then can we introduce specific neurovascular structures into the lesson. An example would be:

“As you are standing in the pterygopalatine fossa, the maxillary artery comes in laterally through the pterygomaxillary fissure (from the infratemporal fossa). Inside the pterygopalatine fossa, the maxillary artery would give several branches, such as the sphenopalatine artery, infraorbital artery and descending palatine artery. These arteries would then exit the pterygopalatine fossa via its respective openings and supply different areas of the face.”

Pre- and Post-Activity Quiz

In this study, a cohort of 80 first-year preclinical students were given a pre- and post-activity quiz to test their understanding of the anatomical space of interest. The pre-activity quiz was given before the 3D paper model activity was conducted, whilst the post-activity quiz was given after the 3D paper model activity had been conducted. The questions asked in the quiz were specifically constructed in relation to the experimental teaching method taught to them as described above. The questions constructed were open-ended short answer questions addressing the “Remembering” domain of Bloom's Taxonomy (10). Students were only required to identify the structure in question. As the questions were specific to the proposed experimental teaching method, all questions and answers were validated and agreed upon by all authors. Table 1 shows the questions that were asked in our quiz. Results of the quiz were analysed using a paired sample t-test to test for significance.

Table 1: Pre and Post Activity Quiz

No.	Question	Answer
1	Name the bone that is anterior to you.	Maxilla
2	Standing in the right pterygopalatine fossa, name the bone that is on your left.	Perpendicular Plate of the Palatine Bone
3	Standing in the right pterygopalatine fossa, name the opening that is on your right.	Pterygomaxillary fissure
4	Standing in the right pterygopalatine fossa, name the opening that is on your left.	Sphenopalatine foramen
5	If you were to jump down in the greater palatine canal, where would you end up in?	Oral cavity
6	If you were to climb up the opening located anterosuperior to you, where would you end up in?	Orbit
7	If you were to exit the foramen rotundum posterior to you, where would you end up in?	Middle Cranial Fossa
8	Standing in the right pterygopalatine fossa, an artery comes in from your right and branches in the fossa. Name that artery.	Third part of Maxillary Artery
9	Name the nerve that enters posterior to you and	Maxillary Nerve

- courses anteriorly into the orbit?
- 10 Name the ganglion that is located in the middle Pterygopalatine Ganglion of the pterygopalatine fossa.
-

DISCUSSION

Human anatomy is a highly visually oriented science subject that requires a mastery of structure, function, and spatial relationships (11). Whilst some anatomical structures can be easily shown in the form of models or gross specimens, some anatomical structures are minute, complex, and difficult to see in cadaveric dissections. Nevertheless, with regard to undergraduate education, these structures or spaces are highly relevant for future clinical applications. As anatomy is a visually oriented subject that requires students to understand shape, structure, and relationships, it is recommended to the teaching staff to demonstrate the structure of interest to the students whether in the form of 2D or 3D representations. As some 3D representations of certain anatomical spaces and areas (as opposed to anatomical models of bones or organs) are difficult to come by and are not readily available, creative ways are needed to help students visualise and appreciate these areas of interest. Innovations in 3D representations of anatomical structures and spaces do not have to be anatomically precise as in the human body, but it has to have enough features and information to assist in students learning and understanding.

Paper models in anatomy teaching and learning are not abundant in the existing literature and are not the go-to method when it comes to anatomy teaching. However, there are anatomical regions that can be translated and simplified into paper models for student understanding. Published paper models of anatomical regions include the middle ear and the temporal bone (12, 13). Both studies were excellent in depicting and simplifying complex anatomical areas into simple paper models. Anatomical paper models do not have to be anatomically precise, but they do have to represent major anatomical features of the area of interest that are important for the learners' understanding. In the case of representing the pterygopalatine fossa as a paper model, the paper model must represent and show the walls, foramina, and structures as well as explain its relationships to other areas of the head. In our paper model, the borders and foramina are accounted for and represented clearly, whereas the neurovascular structures are explained and represented by pipe cleaners as shown in Figure 2. Several key advantages of the proposed paper model are that it is inexpensive and does not require a high level of technological expertise as compared to other technology-based teaching methods such as 3D printing and advanced gaming methods, however, it still retains and delivers the basic level of anatomy knowledge and understanding required at the undergraduate level. Moreover, the pterygopalatine fossa paper model can be constructed, handheld, and appreciated 3-dimensionally, providing an angle that 2D learning does not provide. The proposed paper model also allows students to appreciate and discuss how the neurovascular structures communicate within the fossa as well as with other areas of the head. The simplicity, practicality, and economical aspects of the proposed paper model provide key advantages to teaching institutions that do not have access to high-end teaching models and advanced equipment in their anatomy classrooms. This paper model can be easily replicated and used in any education setting. Though it is advantageous for the undergraduate preclinical setting, we realise the disadvantage of the current pterygopalatine fossa paper

model is that it may not be applicable to a higher-level education setting such as clinical or surgical scenarios. As compared to the study by Chia et al., who proposed a paper-based simulation model for teaching inguinal hernia anatomy for open groin hernia procedures (14), our pterygopalatine fossa paper model was not constructed for surgical simulations. However, this can be further improved in the future revisions of the current paper model.

With regards to the teaching approach, as known by any learner of anatomy, anatomy texts are extremely descriptive and explains well the location, orientation, and relation of any given structure. However, also known by any learner of anatomy, anatomy texts are very dry and do very little in terms of storytelling, as opposed to texts that explain physiological mechanisms or biochemical pathways. Being passionate anatomists, we attempted to incorporate a spatial narrative or spatial storytelling component to rejuvenate anatomy teaching. Narrative, a literary term, is defined as a representation of a series or sequence of events (15). Spatial narrative on the other hand, is a term used in many fields ranging from literature, architecture, geography, and game design, is defined as a designated physical 3D environment in which the characters live and move (16, 17). The term “Narrative Visualisation” has also been used in the field of medical visualization whereby it focuses on communicating medical information to medical experts as well as non-experts (18). In the niche area of medical visualization, narrative visualization combines storytelling techniques with interactive graphics to appeal to a general audience. It aims to explain a particular medical-related phenomenon in a traceable progression that is memorable and easy to understand to both experts and non-experts. There are two types of narrative or storytelling: synchronous and asynchronous storytelling (19). In synchronous storytelling, the narrator is in direct contact with the audience; whereas asynchronous storytelling does not require direct audience contact. These constructed narratives or stories can take the form of recorded videos, static graphics, or visually guided tours through interactive visualisations.

With regards to teaching the anatomy of the pterygopalatine fossa using the 3D paper model, the initial lecture and explanation of the fossa was conducted via synchronous storytelling, whereby the teaching staff explained the anatomy of the pterygopalatine fossa to the students in a physical face-to-face session. Whilst conducting the activity, students had the opportunity to discuss the 3D anatomy of the pterygopalatine fossa with their classmates to further strengthen their understanding. During the spatial narrative explanation, students were taught how to relate the pterygopalatine fossa paper model with anatomical explanations in their lecture notes and textbooks. The pre-activity quiz and post-activity quiz conducted show a significant difference in marks attained by students after the activity when compared to before the activity (significant at $\alpha \leq 0.05$). Though the pre and post-activity quiz simplistically represents students' increase in understanding via the experimental teaching method, further studies should be conducted to test for other factors such as teaching effectiveness, knowledge retention, cognitive load analysis, and assessments in active learning.

As anatomy mastery relies heavily on the ability of the student, as well as the ability of the teacher, to be able to mentally visualise anatomical structures three-dimensionally, this study attempted to introduce the concept of spatial narrative into anatomy education via describing anatomical structures from the perspective of being inside the structure of interest, as opposed to from an external view as traditional anatomy textbooks narrate. This is in line with calls for the importance of integrating 3D visualization and visual-spatial thinking in medical and

dental anatomy education (20, 21). This attempt to introduce spatial narrative in anatomy education will hopefully increase memory retention in anatomy education as supported by several storytelling-driven memory retention techniques (22, 23).

CONCLUSION

This study outlines a novel step-by-step method for creating a 3D paper model of the pterygopalatine fossa as well as introducing an innovative “spatial narrative” teaching approach in anatomy education. This study represents a practical and inexpensive teaching approach to anatomical education in cases where 3D models of an anatomical area are unavailable. Paper model representations of anatomical structures may not apply to all structures of the human body, but for the few that can be modeled through papercraft, it can be beneficial for anatomy learning and teaching and hopefully would act as a precursor for more educational anatomical paper models in the future.

REFERENCES

1. Gibelli D, Cellina M, Gibelli S, Cappella A, Panzeri MM, Oliva AG, et al. Anatomy of the pterygopalatine fossa: an innovative metrical assessment based on 3D segmentation on head CT-scan. *Surg Radiol Anat*. 2019;41(5):523-8.
2. Tashi S, Purohit BS, Becker M, Mundada P. The pterygopalatine fossa: imaging anatomy, communications, and pathology revisited. *Insights Imaging*. 2016;7(4):589-99.
3. Choi J, Park H-S. The clinical anatomy of the maxillary artery in the pterygopalatine fossa. *Journal of oral and maxillofacial surgery*. 2003;61(1):72-8.
4. Masabni O, Ahmad M. Infraorbital foramen and pterygopalatine fossa location in dry skulls: anatomical guidelines for local anesthesia. *Anatomy Research International*. 2017;2017(1):1403120.
5. Javan R, Rao A, Jeun BS, Herur-Raman A, Singh N, Heidari P. From CT to 3D Printed Models, Serious Gaming, and Virtual Reality: Framework for Educational 3D Visualization of Complex Anatomical Spaces From Within-the Pterygopalatine Fossa. *J Digit Imaging*. 2020;33(3):776-91.
6. Bannon R, Parihar S, Skarparis Y, Varsou O, Cezayirli E. 3D printing the pterygopalatine fossa: a negative space model of a complex structure. *Surg Radiol Anat*. 2018;40(2):185-91.
7. Sinav A, Ambron R. Interactive web-based programs to teach functional anatomy: the pterygopalatine fossa. *Anat Rec B New Anat*. 2004;279(1):4-8.
8. Tanner JA, Jethwa B, Jackson J, Bartanuszova M, King TS, Bhattacharya A, et al. A Three-Dimensional Print Model of the Pterygopalatine Fossa Significantly Enhances the Learning Experience. *Anatomical Sciences Education*. 2020;13(5):568-80.
9. Velde MHvd. *templatemaker.nl* : Pyramid Box [Available from: <https://www.templatemaker.nl/en/pyramid/>].
10. Anderson LW, Krathwohl DR, Airasian PW, Cruikshank KA, Mayer RE, Pintrich PR, et al. A revision of Bloom’s taxonomy of educational objectives. *A Taxonomy for Learning, Teaching and Assessing* Longman, New York. 2001.

11. Van Sint Jan S, Crudele M, Gashegu J, Feipel V, Poulet P, Salvia P, et al. Development of multimedia learning modules for teaching human anatomy: application to osteology and functional anatomy. *The Anatomical Record Part B: The New Anatomist: An Official Publication of the American Association of Anatomists*. 2003;272(1):98-106.
12. Guy J, Muzaffar J, Coulson C. Teaching middle ear anatomy using a novel three-dimensional papercraft model. *Eur Arch Otorhinolaryngol*. 2021;278(8):2769-74.
13. Hiraumi H, Sato H, Ito J. Papercraft temporal bone in the first step of anatomy education. *Auris Nasus Larynx*. 2017;44(3):277-81.
14. Kong CY, Iddles E, Glen P. A Paper-Based Simulation Model for Teaching Inguinal Hernia Anatomy. *World J Surg*. 2023;47(8):1842-9.
15. Rudrum D. From narrative representation to narrative use: Towards the limits of definition. *Narrative*. 2005;13(2):195-204.
16. Buchholz S, Jahn M. Space in narrative. *Routledge encyclopedia of narrative theory* London: Routledge. 2005:551-5.
17. Kujundžić N. Narrative space and spatial transference in Jacob and Wilhelm Grimm's fairy tales: University of Zagreb. University of Zagreb, Faculty of Humanities and Social ...; 2020.
18. Meuschke M, Garrison L, Smit N, Bruckner S, Lawonn K, Preim B. Towards narrative medical visualization. *arXiv preprint arXiv:210805462*. 2021.
19. Lee B, Riche NH, Isenberg P, Carpendale S. More than telling a story: Transforming data into visually shared stories. *IEEE computer graphics and applications*. 2015;35(5):84-90.
20. Mathewson JH. Visual-spatial thinking: An aspect of science overlooked by educators. *Science education*. 1999;83(1):33-54.
21. Triepels CP, Smeets CF, Notten KJ, Kruitwagen RF, Futterer JJ, Vergeldt TF, et al. Does three-dimensional anatomy improve student understanding? *Clinical Anatomy*. 2020;33(1):25-33.
22. Robertson C, Clegg G, Huntley J. *Storytelling in medicine: How narrative can improve practice*: CRC Press; 2023.
23. Colak T, Orha AT, Tavas O, Aksu E, Guzelordu D, Sivri I, et al. A New Method in Anatomical Education of Medical Faculty: Storytelling. *Journal of the Anatomical Society of India*. 2021;70(2):75-80.